



Audrey Pace

Alison Murray and Jonathan Sandler

Orthognathic Surgery: 1. When did it all start?

Abstract: An increasing number of patients are being referred by their general dental practitioners for consideration of an orthognathic approach to treatment. This is the first of two papers discussing the origins as well as the scope and limitations of orthognathic surgery when combined with orthodontic treatment. This report details the historical progression of orthognathic surgery since it was first performed more than a hundred years ago.

Clinical Relevance: The practitioner should understand the importance of the multidisciplinary approach in the management of orthognathic cases.

Ortho Update 2010; 3: 6–8

Orthognathic surgery, a term originating from the Greek words *orthos*, 'straight' and *gnathos*, 'jaw',¹ is considered to be a specialist branch of oral and maxillofacial surgery which is closely associated with orthodontic treatment. It involves surgical correction of dentofacial deformities after the patient has had preparatory orthodontic treatment for the correction of the underlying malocclusion. The overall aim is to attain an improvement in the form and function by correcting occlusal, skeletal and aesthetic aspects.

The historical development of orthognathic surgery has followed a tortuous path. One cannot fully appreciate the current achievements unless the challenges of earlier surgeons and orthodontists are thoroughly understood. Much of the literature by necessity deals with successful cases and positive technical improvements, leaving many of the failures almost certainly unreported.

Mandibular osteotomies

The first documented surgical procedure for correction of dentofacial deformity was carried out by a general surgeon who had additional expertise in dentistry, by the name of Hullihen in Virginia, USA, in 1849² (Figure 1). The patient

was a 20-year-old girl who had sustained severe burns to the lower face and neck 15 years previously. He performed the surgical procedure in three stages, including a mandibular osteotomy and extensive soft tissue surgery, all undertaken without any form of anaesthesia.³ However, it was the 'St Louis Operation' in 1897, led by another general surgeon, Vilray Blair, and assisted by 'The Father of Modern Orthodontics', Edward Angle,² that really pioneered the osteotomy procedures and subsequently orthognathic surgery.¹ They were the first to realize the benefits of co-operation between orthodontists and surgeons, and believed that both orthodontics alone and surgery alone had limits in the comprehensive treatment of dentofacial deformities.

Blair wrote in 1907:

*The treating of skeletal deformities is really surgical work, but the earlier a competent, congenial orthodontist is associated with the case, the better it will be for both the surgeon and the patient.*²

At a later stage, Blair was also the first person to describe a 'classification' of jaw deformities, namely: mandibular prognathism, mandibular retrognathism, alveolar mandibular and maxillary



Figure 1. Simon P Hullihen 'The Father of Oral Surgery'. (Permission of Prof KF Moos, Hon Senior Research Fellow, Department O&M Surgery, Glasgow Dental School.)

protrusion and open bite.¹

Berger (1897) from Lyon, France, described a condylar osteotomy for a prognathic malocclusion, however, this had less than satisfactory results.¹ Unfortunately, progress in orthognathic surgery came to a halt during World War I, when surgeons

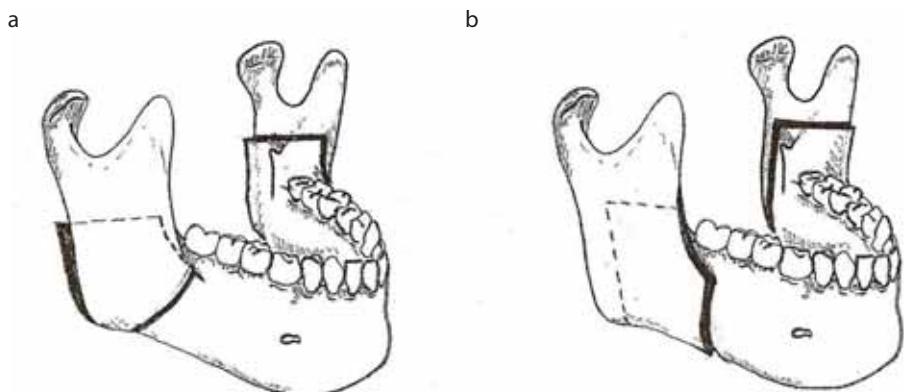


Figure 2. The development of the sagittal split ramus osteotomy of the mandible: (a) Obwegeser procedure (1957); (b) Dal Pont modification (1958).



Figure 3. Sir Harold Gillies. (Permission of Dr Andrew Bamj, Curator, Gillies Archives, Queen Mary's Hospital, Sidcup.)



Figure 4. Paul Tessier. (Permission of Countway Library of Medicine, Boston, Mass.)

were more committed to treating traumatic facial injuries and could give little time to new developments in the correction of congenital facial deformity.

After the end of The Great War, a number of enthusiastic surgeons, including Perthes (1922), Pichler (1928), Wassmund (1935) and Dingman (1944), published a number of reports detailing techniques for the correction of common deformities, mainly for open bite and prognathism.⁴ On the whole, most of these techniques were not terribly successful and were not applied to everyday clinical practice. One example of this would include the 'blind' Gigli saw technique, described by Kostecka, which was originally designed for correction of

open bite but was later used by Schaefer for correction of prognathism.⁴

The introduction of the bilateral sagittal split ramus osteotomy, originally described by Köle and Hugo Obwegeser and later modified by Dal Pont in 1958, was a major landmark in orthognathic surgery. By the late 1970s, the procedure was further modified to become a very popular intra-oral orthognathic procedure to correct severe Class II and Class III malocclusions⁵ (Figure 2).

Genioplasty

The first attempt of an extra-oral approach to genioplasty was carried out by Hofer in 1942.⁶ In 1957, Obwegeser achieved a better end result by adopting the intra-oral approach, however, more successful results were reported by Köle in 1959 when he advanced and shortened the chin in a single procedure.²

Maxillary osteotomies

Interest in maxillary osteotomies began in 1864 when Cheever was the first to downfracture the maxilla. Only after many years did the famous Rene Le Fort (1901) carry out a lot of experimental work on cadaver skulls in order to identify sites in the midface where fractures were most likely to occur.³ Wassmund then utilized the findings from Le Fort's work to perform a maxillary osteotomy but, unfortunately, the results were not satisfactory as he applied orthopaedic traction rather than full mobilization of the maxilla.⁴ The concept of producing full mobilization was not initially accepted because of the fear of developing bone necrosis and teeth devitalization. In 1965, Obwegeser observed that retaining a soft tissue pedicle to the palatal mucosa preserved the blood supply to the maxilla and hence minimized the risk of developing post-operative bone necrosis.⁴

The Le Forte III midface osteotomy was first described by Sir Harold Gillies (Figure 3) on a patient with Crouzon deformity.³ Obwegeser was the first surgeon to carry out a combined maxillary and mandibular osteotomy procedure during the same operation, thus giving rise to bimaxillary osteotomies.¹

Methods of fixation

In the past few decades, fixation methods have been the main aspect of development in orthognathic surgery. Initially, orthognathic procedures utilized splints on teeth and intermaxillary fixation for up to 5–6 weeks.³ New methods of internal rigid fixation, originally proposed by our orthopaedic colleagues, have radically decreased morbidity and made surgery more predictable.¹ The concept of bone plating began in 1917 when a gold wedding ring was transformed into a plate to stabilize a mandibular fracture!³ In the 1960s, the Swiss osteosynthesis group AO (Arbeitsgemeinschaft für Osteosynthesefragen) developed various sizes of mandibular compression bone plates. Bernd Spiessl was the first maxillofacial surgeon who applied the AO principles for the fixation of a sagittal split osteotomy and he strongly believed in compression osteosynthesis, a concept that is now considered less important for bone healing in orthognathic surgery. Biologically inert resorbable implants have been one of the latest developments but, despite the fact that they offer several theoretical advantages over the standard materials, they are nowadays more widely used in paediatric craniofacial surgery.⁷

Procedure	Finished consultant cases	Mean length of stay (days)	Mean age	Predominant sex
Low level Le Fort I	1241	2.6	24y	Female
BSSO (advancement)	505	2.2	26y	Female
BSSO (setback)	120	2.5	25y	Female
Genioplasty	138	1.4	27y	Female

Table 1. Inpatient statistics (2007–2008).⁹

Date	Surgeon	Location	Procedure
1849	Hullihen	USA	First recorded osteotomy procedure
1897	Blair	USA	'St Louis Operation'
1922	Perthes	Vienna	Extra-oral vertical osteotomy of the mandibular vertical ramus ⁴
1931	Kostecka	Prague	'Blind procedure' with the Gigli saw
1935	Wassmund	Germany	Anterior maxillary osteotomy Le Fort I osteotomy ⁴
1942	Gillies	UK	Le Fort III midface osteotomy ³
1955	Trauner	Vienna	Mandibular osteotomy at the mandibular angle
1955	Schuchardt		Two-stage anterior maxillary osteotomy Posterior maxillary osteotomy ⁴
1959	Köle	Graz	Augmentation genioplasty Modification of anterior mandibular osteotomy ⁴
1957	Obwegeser	Zurich	Augmentation genioplasty Sagittal osteotomy of the mandibular vertical ramus ⁴
1958	Dal Pont	Italy	Modification of sagittal split osteotomy
1967	Tessier (Figure 4)	France	Modification of Gillies Le Forte III osteotomy Foundations of reconstructive surgery
1974	Spießl	Germany	Internal rigid fixation techniques

Table 2. Major contributors to orthognathic surgery.

As orthognathic treatment has become more widely available and more socially acceptable, the demand for it has increased enormously (Table 1). Our society is less tolerant to 'deviations from the norm' and much more open to surgical procedures. Cunningham reported that, over the 9-year period between 1997 and 2006, the NHS Hospital Episode Statistics (HES) database produced records of a total of 9080 mandibular orthognathic surgical procedures done for 8941 individual patients in England. The mean age at operation was 24 years, with females being the predominant sex.⁸

Conclusion

This first paper has given the historical development of osteotomy procedures, from early unsophisticated operations performed in the 19th and 20th Centuries (Table 2), in the early days without the aid of anaesthetics, through to the multidisciplinary work-up and execution of complex bimaxillary

procedures performed today.

The second part of this paper will detail the range and scope of modern orthognathic procedures and will describe the information that dentists and orthodontists should be giving to their patients when thinking of embarking upon this course of treatment.

References

1. Panula K. Correction of dentofacial deformities with orthognathic surgery: Outcome of treatment with special reference to costs, benefits and risks. University of Oulu; Oulu University Library, 2003.
2. Steinhauser EW. Historical development of orthognathic surgery. *J Cranio-maxillofac Surg* 1996; **24**: 195–204.
3. Moos KF. Origins of orthognathic surgery. *Lindsay Club Newsletter* April 2000; **37**: 5–18.
4. Caldwell JB, Gerhard RC, Lowry RE. Orthognathic surgery. In: *A textbook of oral and maxillofacial surgery*. Kruger GO, Philadelphia: CV Mosby, 1984: pp. 514–639.
5. Ward Booth P. Orthognathic surgery. In: *Maxillofacial surgery* 2. Ward Booth P, Schendel S, Hausamen JE. St Louis: Elsevier, Churchill Livingstone, 2006: pp.1155–1289.
6. Fonseca RJ. The biological, physiological and psychosocial basis of facial skeletal surgery. In: *Oral and Maxillofacial Surgery III*. Fonseca RJ, Marciani RD, Turvey TA. St Louis: Elsevier, Saunders, 2009: pp.60–76.
7. Mohamed-Hashem KI, Mitchell DA. Resorbable implants (plates and screws) in orthognathic surgery. *Br J Orthod* 2000; **27**: 198–199.
8. Cunningham SJ, Moles DR. A national review of mandibular orthognathic surgery activity in the National Health Service in England over a nine year period. Part 2 – Patient factors. *Br J Oral Maxillofac Surg* 2009; **47**: 274–278.
9. NHS Hospital Episode Statistics (HES) database <http://www.hesonline.org.uk/Ease/servlet/ContentServer?siteID=1937&categoryID=215>