



Anwar A Shah

Jonathan Sandler

# Limiting Factors in Orthodontic Treatment: 2. The Biological Limitations of Orthodontic Treatment

**Abstract:** Owing to a shortage in the orthodontic workforce in the United Kingdom, general dental practitioners carry out orthodontic treatment in selected cases. Orthodontic treatment may not always be successful due to various factors. Some of these limiting factors are related to the practitioner, others to the patients and the orthodontic appliances used. These three sets of factors were covered in the first part of this article. This second part deals with the biologic limitations of orthodontic treatment.

**Clinical Relevance:** General dental practitioners and novice orthodontic practitioners may get into difficulties by embarking upon an orthodontic treatment which may not be feasible due to various limitations imposed by the underlying biology. This article provides a brief outline of these limitations.

**Dent Update 2006; 33: 100-110**

Considerable limitations in the clinical application of orthodontic treatment can result from many factors related to the patient, operator, orthodontic appliance and biology (Table 1). In the first part of this article, we described the factors which are related to patient, operator and

orthodontic appliances (Factors 1–3, Table 1). In this part, we describe the biological factors, which can limit orthodontic treatment.

## Biological factors

### Patient age

Treatment of most malocclusions is best carried out during the early teenage period, when advantage can be taken of active growth and rapid cell turnover. Quite marked skeletal II problems are amenable to orthodontic treatment if a patient is seen early enough before the adolescent growth spurt. For example, a child with a retrognathic mandible at age 12 may be treated with a functional appliance (eg a twin block appliance) as described in the first part of this article.

If a patient with a skeletal problem misses out on orthodontic

treatment during the active growth period, it is often difficult to achieve a satisfactory result with orthodontic treatment alone. Such patients may need combined orthodontic and surgical treatment at a later date after mandibular growth has largely ceased.

Similarly, a bilateral posterior crossbite may be corrected orthodontically using rapid maxillary expansion during adolescence. This type of expansion is more suitable when the crossbite is associated with a narrow maxilla owing to skeletal discrepancy in the transverse plane. Once the patient is over the age of 16, when ossification of the midpalatal suture has occurred, it may not be possible to correct the problem with orthodontic treatment alone because of the increased interdigitation of the sutures.<sup>1,2</sup> Such patients may benefit from surgically-assisted rapid maxillary expansion.

Many adult patients are

**Anwar A Shah**, BDS(Hons), FDS RCS, PhD, FFD RCSI, MOrth RCS, Clinical Lecturer in Orthodontics, Department of Oral Health and Development, School of Clinical Dentistry, University of Sheffield, S10 2TA and Specialist Registrar in Orthodontics, Chesterfield and North Derbyshire Royal Hospital, Calow, Chesterfield, Derbyshire, S44 5BL and **Jonathan Sandler**, BDS(Hons), FDS RCPS, MSc, MOrth RCS, Consultant Orthodontist, Chesterfield and North Derbyshire Royal Hospital, Calow, Chesterfield, Derbyshire, S44 5BL.

**1. Patient factors**

- Age
- Attitude
- Poor patient compliance
  - Diet
  - Oral hygiene
  - Elastics
  - Headgear
- Habits
  - Thumb sucking
  - Endogenous tongue thrust

**2. Operator factors**

- Knowledge and clinical ability
- Availability of resources
- The clinical goals of the operator
- Communication skills

**3. Appliance factors**

- Removable appliances
- Functional appliances
- Fixed appliances
- Headgear

**4. Biological factors**

- Patient age
- Patient health
  - General medical health
  - Dental health
- Anatomical factors
  - Hard tissue factors
    - Skeletal discrepancy
    - Amount of alveolar bone
    - Dental compensation
    - Severity of crowding
    - Root morphology
    - Number of teeth
      - Hypodontia
      - Supernumerary
    - Morphology of tooth crown
    - Ankylosed teeth
  - Soft tissue factors
    - Naso-labial angle
    - Fraena
    - Mobility of mucosa
    - Lack of attached gingiva
- Pathology such as a cystic lesion
- Stability/relapse issues

**Table 1.** A summary of the factors which can limit orthodontic treatment.

now seeking orthodontic treatment. An orthodontic problem, which is usually straightforward treatment at an earlier stage of life, may be beyond the scope of orthodontic treatment in an adult patient. A deep overbite, for instance, may not be as simple to treat in an adult because correction will normally require a significant increase in the facial height, usually by a combination of posterior teeth extrusion and anterior teeth intrusion. Such an increase in the facial height may not be stable in the long term unless a concomitant increase in the mandibular ramus height occurs, which is unlikely in the non-growing adult patient.

Adult patients' expectations of orthodontic treatment are often high and the lack of active growth, in association with periodontal and restorative problems, may limit the aims of the orthodontic treatment.

**Patient health****General medical health**

Patients' general medical health should be evaluated from their medical history and clinical examination.

Orthodontic treatment is an elective procedure and there are frequently several options open to the practitioner. Comprehensive orthodontic treatment is less likely to be indicated for chronically ill patients. These patients may, however, benefit from orthodontic treatment in selected cases. The most important medical conditions which may limit orthodontic treatment are:

- Bleeding disorders
- Sickle cell anaemia
- Treated leukaemia
- Diabetes mellitus
- Cystic fibrosis
- Arthritis and
- Cardiovascular diseases.

In addition to the classic inherited sex-linked form of haemophilia, a number of other types of haemophilia caused by clotting factor deficiencies have been recognized. These are important from two points of view: first, children with haemophilia may have hepatitis as a result of receiving multiple blood transfusions and all measures should be taken to prevent cross-infections; secondly, intra-oral haemorrhage is a great risk and any invasive procedure in such

patients should be carried out only after discussion with the patient's physician. In such patients, fixed appliances are preferable to removable appliances, as the latter may cause chronic irritation and gingival bleeding. In addition, treatment with functional appliances is less desirable, as such treatment may induce bleeding in the temporomandibular joints.<sup>3</sup> In a haemophilic child with a skeletal II malocclusion, orthognathic surgery may be a better choice than the apparently safer and more conservative treatment with a functional appliance.<sup>3,4</sup>

Sickle cell trait and sickle cell anaemia result from the presence of an abnormal form of haemoglobin, haemoglobin S, in red blood cells. The prevalence of this disease is higher in African children. Extraction of teeth for orthodontic treatment under general anaesthesia should be avoided in such patients, as it may reduce blood oxygen saturation. Orthodontic treatment should have well-defined goals and should be as short as possible. Orthognathic surgery is contra-indicated in such patients owing to anaesthetic risks.

Children with treated leukaemia may have undergone chemotherapy or radiation therapy. No orthodontic treatment should be carried out during, or soon after, chemotherapy or radiation therapy. Orthodontic treatment, however, may be offered during long-term remissions if the child is not receiving chemotherapy. Such a treatment must be carried out only after consulting the patient's physicians. Antibiotic prophylaxis may be indicated for invasive procedures. Treatment with fixed appliances is preferable and bonded attachments should be used instead of using bands on molar teeth. Such patients may have a severe xerostomia due to their chemotherapy and radiation therapy and orthodontic treatment may be contra-indicated.

Diabetes mellitus is another medical condition which should be considered here. Orthodontic treatment should not be provided to a patient with uncontrolled diabetes mellitus. If the diabetes is well controlled, orthodontic treatment may be offered but the patient must be monitored carefully for any intra-oral signs of uncontrolled diabetes such as periodontal disease.

Cystic fibrosis is an autosomal

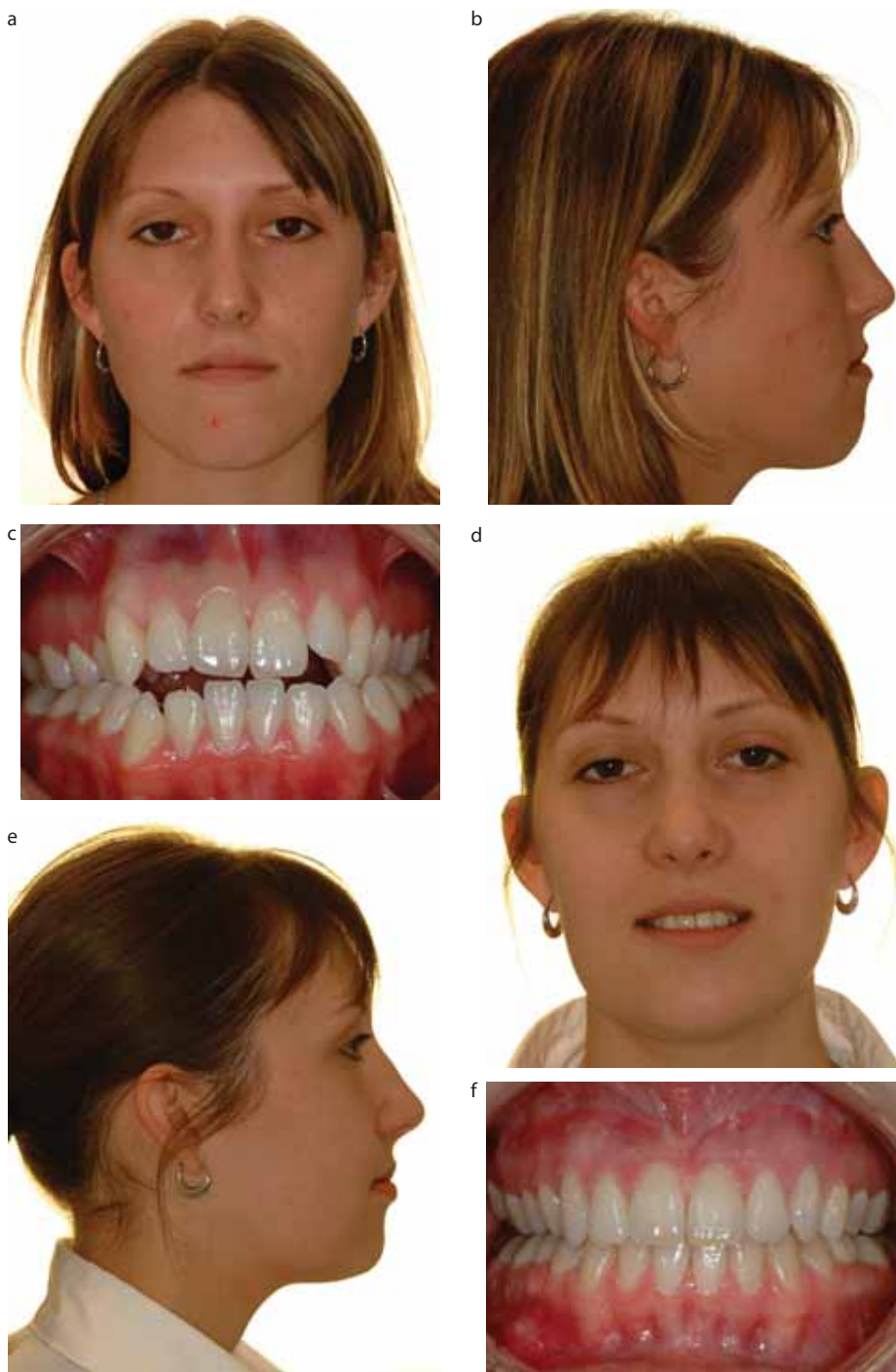


Figure 1. (a-f) A skeletal III malocclusion which needed combined orthodontic and surgical treatment.

recessive disorder of the exocrine glands involving the mucous glands of the pulmonary and digestive system. Children with cystic fibrosis should have a very limited orthodontic treatment if attempted.<sup>5</sup> Extraction of teeth should be carried out under local anaesthesia,

if necessary combined with inhalation sedation.

Rheumatoid arthritis is a condition which may involve the temporomandibular joint. It usually affects multiple symmetrical small joints, and any patient who gives a history of rheumatoid

arthritis in other joints of the body should alert the clinician to the possible involvement of the temporomandibular joint. In such patients, the use of functional appliances to correct skeletal II discrepancy, heavy intermaxillary Class II elastics and surgical advancement of the mandible should be avoided.<sup>3</sup>

**Dental health**

Poor oral hygiene is a contra-indication for orthodontic treatment. Similarly, patients with decayed teeth should not be provided with any orthodontic treatment until the carious lesions are fully treated. Finally, untreated periodontal disease is another major contra-indication for orthodontic treatment and one should not attempt to move a tooth before the active periodontal disease has been treated, otherwise loss of periodontal support may be accelerated.<sup>6,7</sup> In selected cases, very light forces of very short duration may be used to move such teeth orthodontically provided the periodontal tissues are healthy, having responded favourably to periodontal therapy. Regular periodontal recall must be maintained throughout and after orthodontic tooth movement in these cases. However, orthodontic treatment for patients with periodontal problems should not be attempted by the non-experienced and without an expert periodontal input.

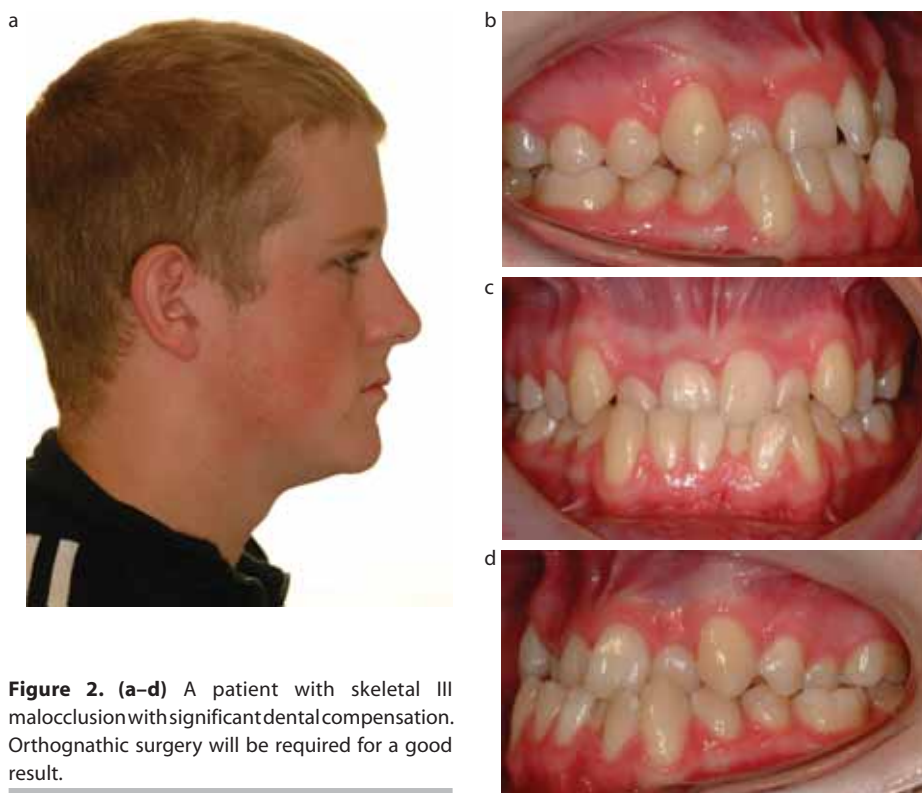
**Anatomical factors**

● **Hard tissue factors**

**Skeletal discrepancy**

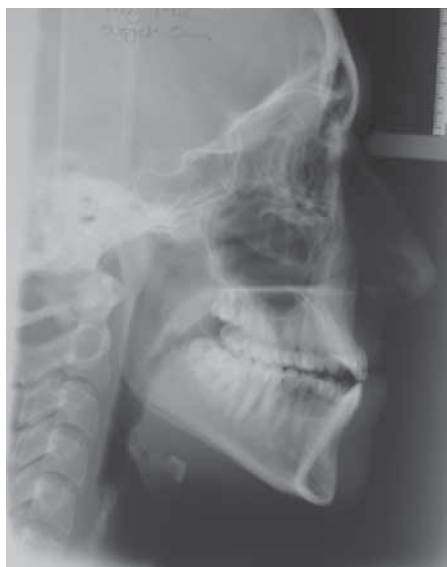When there is a significant underlying skeletal discrepancy, there is little chance that orthodontic treatment alone will produce 'normal' relationships of the jaws, teeth and soft tissues. A severe skeletal Class III, Class II skeletal pattern or an open bite due to skeletal discrepancy may be impossible to treat successfully by orthodontics alone. Such patients may need combined surgical and orthodontic treatment (Figure 1).

Usually, where there is a skeletal discrepancy, there is also some dental compensation. For example, there may be retroclination of the lower incisors and proclination of the upper incisors in skeletal III discrepancy, which may camouflage the underlying problem. A mild to moderate skeletal discrepancy

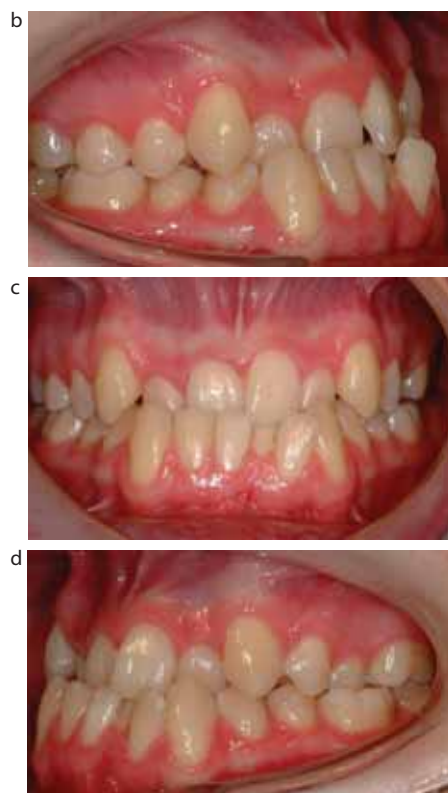


**Figure 2. (a–d)** A patient with skeletal III malocclusion with significant dental compensation. Orthognathic surgery will be required for a good result.

may be camouflaged with orthodontic treatment alone if there is not already too much dental compensation. If there is significant dental compensation, camouflage treatment may not be possible



**Figure 3.** A cephalogram showing a thin lower labial cortical bone.



cortical bone before such a treatment is planned, as proclination of incisors may jeopardize their long-term prognosis (Figure 3). Similarly, it may not be possible to move the roots of the upper incisors if the palatal cortical bone is thin.

If there are long-standing extraction spaces, especially in adult patients, the 'necking' of the alveolar bone may prevent, or at least delay, tooth movement into these spaces (Figure 4). Generally, by moving teeth into such spaces, the bucco-lingual width of the alveolar bone will be increased but the vertical bone may reduce at the same time.<sup>9</sup>

Where there is severe lack of any alveolar bone, moving a tooth in such a space should not be undertaken. Such a situation exists in cleft palate patients in the repaired cleft area (Figure 5). In such cases, an alveolar bone graft should be carried out prior to any orthodontic movement of the canine tooth.

#### **Amount of crowding**

Severity of dental crowding can impose limitations on success of orthodontic treatment. If there is a severe tooth size/arch length discrepancy, extraction of one tooth in each quadrant may not create enough space for alignment of the teeth. In such cases, extraction of two teeth in one or more quadrants may be required to align the teeth (Figure 6). Some patients may be reluctant to consent to extraction of more than one tooth per quadrant and this will affect a successful orthodontic outcome.

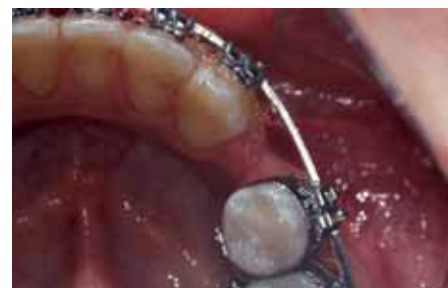It is not uncommon for some patients to present with severe crowding and/or dental centre line discrepancy who have had previous extractions for crowding relief which was never followed

and a combined surgical and orthodontic treatment may be the only option to get an acceptable result (Figure 2). Such patients must be warned at the beginning of the treatment that, at the end of pre-surgical orthodontic treatment, the discrepancy will get significantly worse in preparation for the surgery.

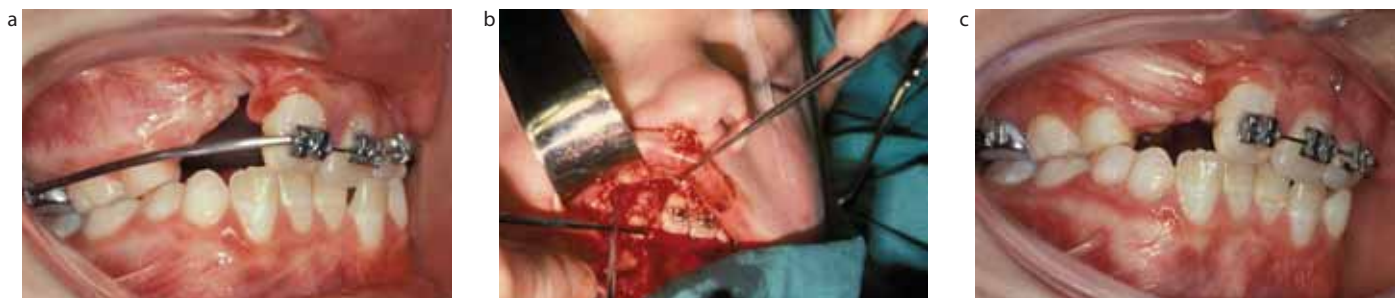#### **Alveolar bone**

The amount of bone available into which teeth can be moved is a factor which can limit orthodontic treatment. The lower labial cortical bone is usually thin but, in some patients, this is markedly so. A thin alveolus may be seen in patients with any skeletal pattern, but it frequently occurs in patients with a Class III skeletal pattern, increased lower face height and severe bimaxillary protrusion.<sup>8</sup>

Usually, unless surgery is being planned, the lower incisors are maintained as close as possible to their pre-treatment position in the labiolingual plane. In a few cases, however, proclination of lower incisors may be a planned movement and is also likely when decompensation of a severe Class III case precedes a mandibular setback. It is prudent to check the labial



**Figure 4.** Long-standing extraction space in the lower first premolar region.



Figures 5. (a–c) Alveolar bone graft in patient with a cleft.

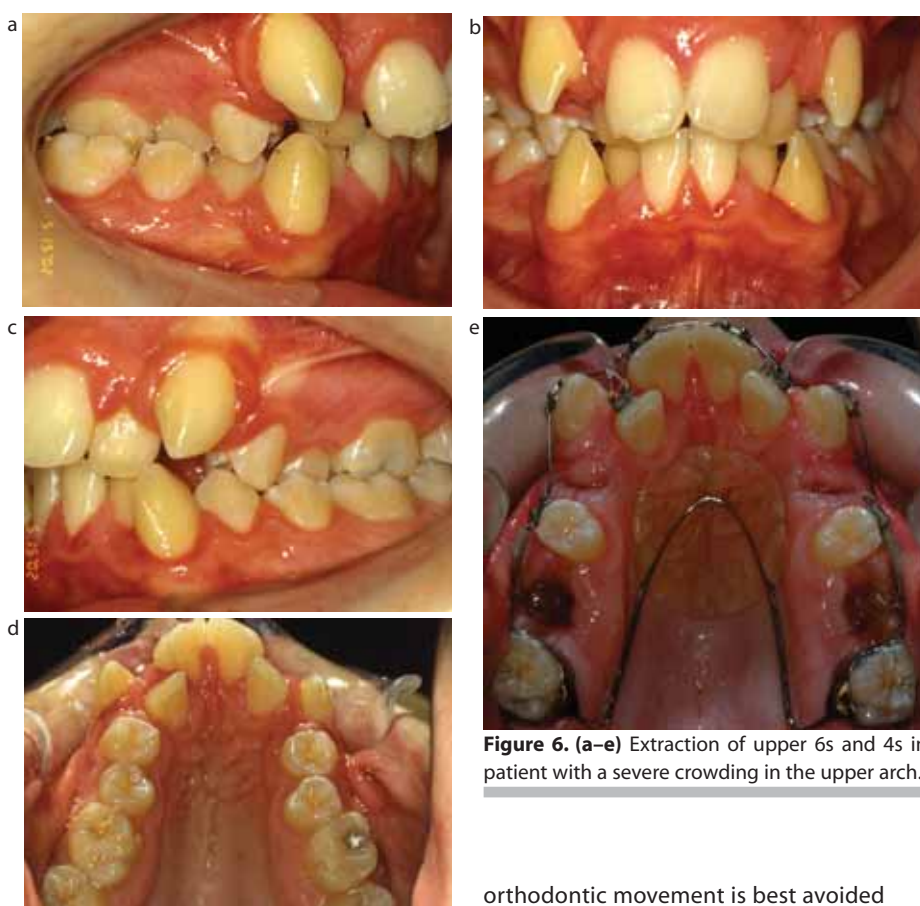


Figure 6. (a–e) Extraction of upper 6s and 4s in patient with a severe crowding in the upper arch.

up by active orthodontic treatment. Patients with such a handicapped dentition pose a great challenge to treat, as there is still a significant space requirement, despite the fact that teeth have already been lost.

**Root morphology**

Root morphology is one of the factors which may be associated with an orthodontic root resorption. Blunt, bent, short or pipette-shaped roots are associated with a greater risk of root resorption<sup>10</sup> (Figure 7). In such cases, any

orthodontic movement is best avoided and, if orthodontic movement is necessary, very light forces must be used for a short period.<sup>10</sup>

**Number of teeth**

In patients with severe hypodontia, a multidisciplinary approach is usually required, as orthodontic treatment alone can offer only a limited solution to the malocclusion (Figure 8). The restorative dentist needs to be consulted first and, after all clinicians agree the treatment plan, orthodontic treatment is undertaken. Usually, some prostheses in the form of crowns, bridges and/or implants are required in these patients.

The orthodontist’s role is essentially to redistribute the spaces and provide optimal tooth position to allow high quality prostheses to be placed.

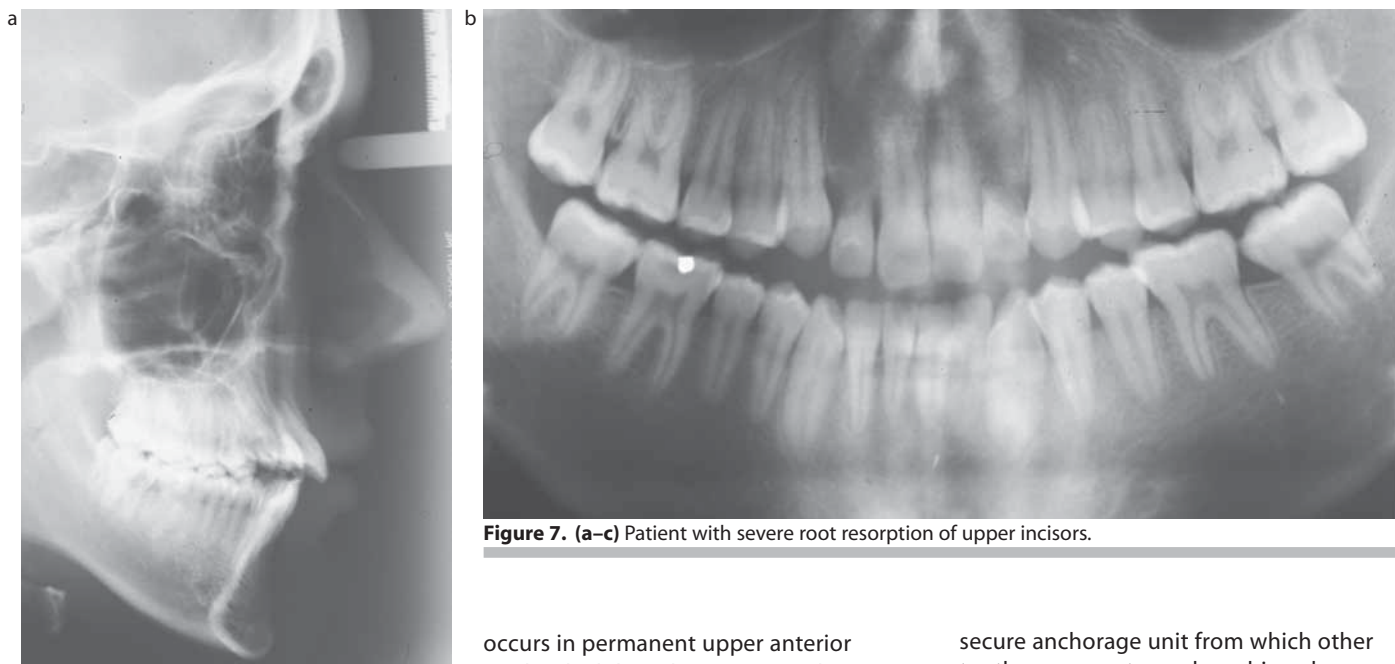
Supernumerary teeth are not common, but the majority of these teeth occur in the anterior maxillary area.<sup>11</sup> The conical and tuberculate forms are the commonest types. The conical supernumerary teeth (eg mesiodons) usually do not prevent the eruption of incisors, but the tuberculate form, which occurs in pairs, may delay the eruption of incisors. Tuberculate supernumeraries often need to be removed to allow incisor eruption. However, only 50% of previously impacted incisors will erupt spontaneously.<sup>12</sup> Treatment of patients with supernumerary teeth should be preferably carried out in hospital where the input from a variety of specialists can be co-ordinated in the patient’s best interest.

**Morphology of teeth**

Abnormal tooth shape and size can occur in isolation or in conjunction with other problems. Many hypodontia patients, for instance, have peg-shaped upper lateral incisors. Oversized teeth, as a result of gemination or fusion, or macrodonts from other causes always pose limitations on what can be achieved (Figure 9). In all these cases, a restorative input is mandatory to give the patient the best possible occlusion, both functionally and aesthetically.

**Ankylosis**

Ankylosed teeth present a great challenge to the success of orthodontic treatment, as these teeth are impossible to move. Usually, ankylosis



**Figure 7. (a–c)** Patient with severe root resorption of upper incisors.

occurs in permanent upper anterior teeth, which have been previously traumatized, or where their predecessors were traumatized. However, ankylosis of permanent molars is not uncommon<sup>13</sup> (Figure 10). Ankylosed teeth produce a metallic ‘cracked tea cup’ sound with a resonance when percussed with the dental mirror. Very rarely, however, ankylosed teeth can be a ‘blessing in disguise’ for the orthodontist as they can be used as a

secure anchorage unit from which other tooth movements can be achieved.

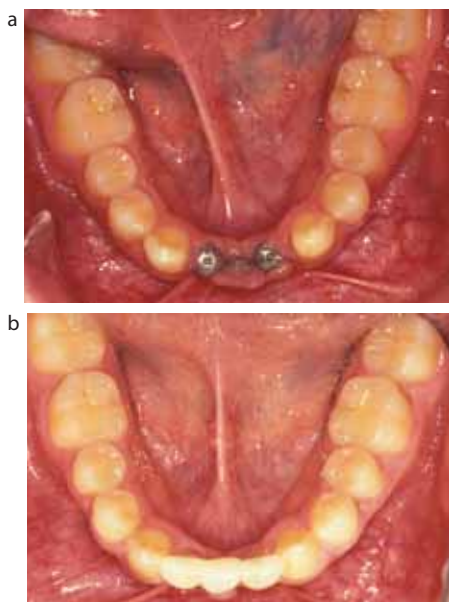
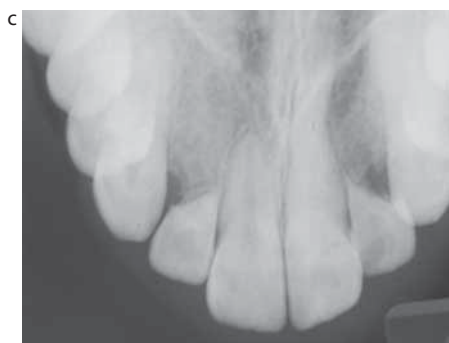● **Soft tissue factors**

**Naso-labial angle**

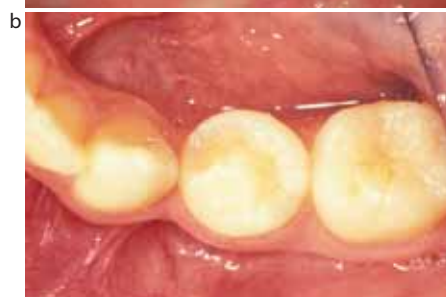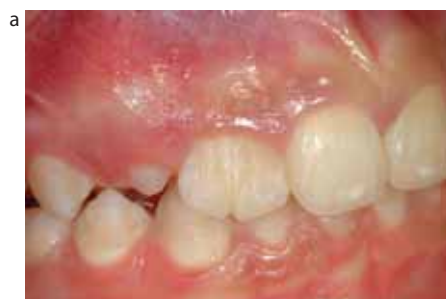Patients may present with an obtuse naso-labial angle and associated dental crowding or proclination of upper incisors. Such patients may need extraction in the upper arch for the relief of crowding and to correct the proclination of upper incisors. However, retraction of upper incisors will be detrimental to the facial appearance, as it may increase the naso-labial angle even further.<sup>14</sup> In such cases, the obtuse naso-labial angle limits the scope of orthodontic treatment alone and, depending on other relevant factors, such patients may need combined surgical and orthodontic treatment, or a compromised result including an increased overjet may need to be accepted for satisfactory facial aesthetics.

**Lack of attached gingiva**

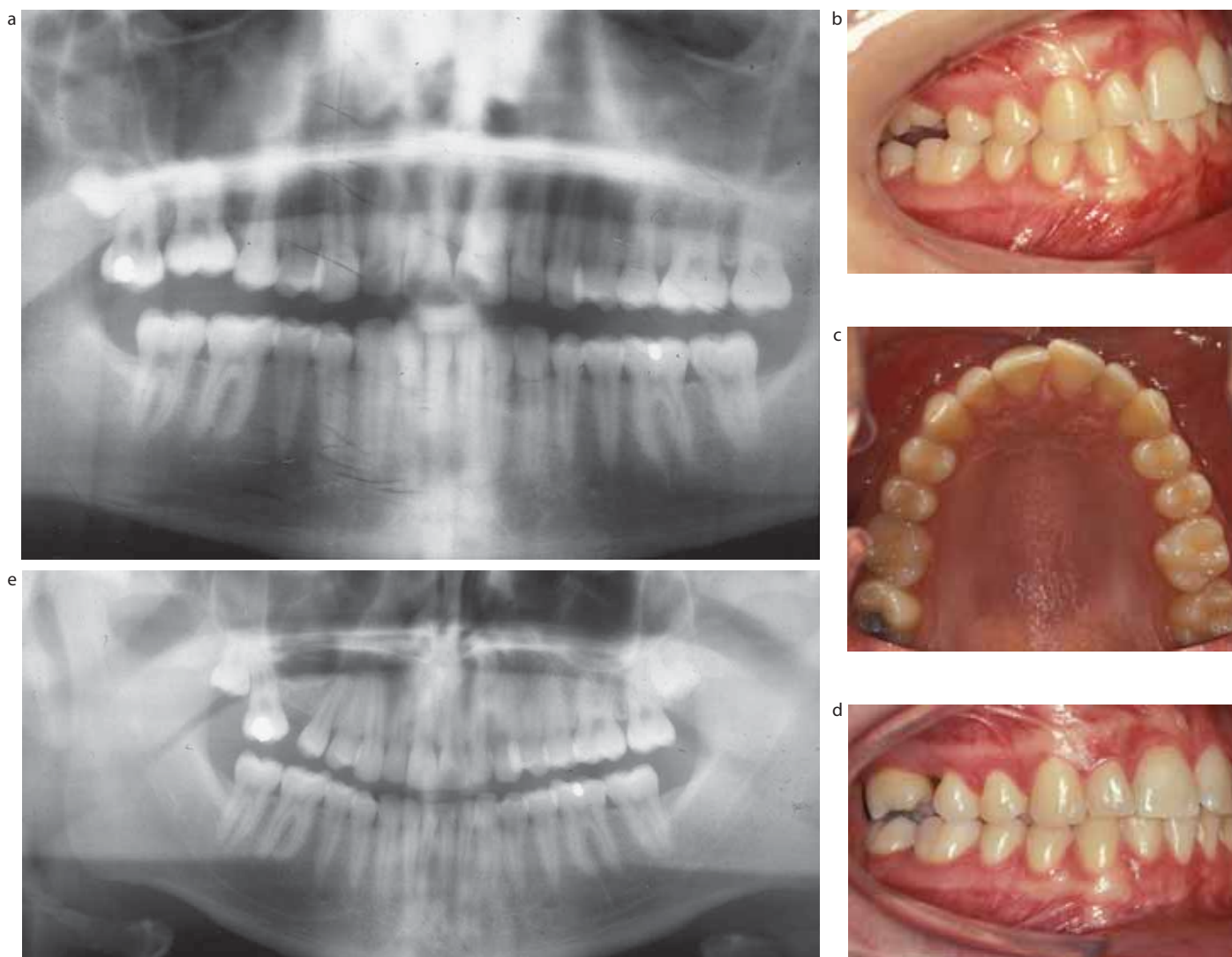
Patients may have thin and friable tissue and very little attached gingiva on the labial aspect of the lower incisors or in the canine-premolar region (Figure 11). Such patients are particularly vulnerable to further gingival recession if the lower incisors are moved labially. Therefore, possible tooth movements are limited. If the oral hygiene is poor, the gingival recession may get even worse. The lower labial gingiva in these patients



**Figure 8. (a–b)** Patient with missing incisors who needed a combined orthodontic and restorative treatment.



**Figure 9. (a)** Patient with gemination of upper lateral incisor. **(b)** Patient with a macrodont of lower second premolar.



**Figure 10. (a–e)** Ankylosed upper right first permanent molar had to be extracted to allow spontaneous alignment of upper second molar.

may be augmented prophylactically with mucogingival surgery.<sup>15</sup>

Gingival recession may occur on the buccal surfaces of maxillary molars and premolars in patients who are treated with inappropriate maxillary expansion. This may once again limit the possibilities for tooth movement.

#### **Eruption through movable mucosa**

In some patients, there is a lack of attached gingiva over an erupting tooth and the tooth is often unable to erupt through movable mucosa, or fraenal attachments may be preventing eruption.<sup>16</sup> Simple soft tissue surgery usually resolves the problem of the eruption failure and carefully executed surgery can provide

satisfactory gingival attachment in these cases.

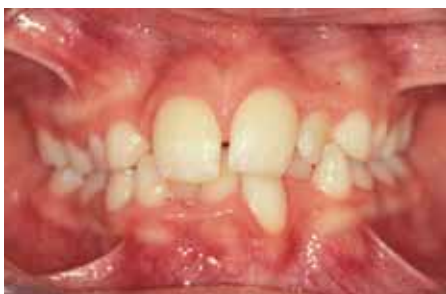#### **Fraena**

The labial fraenum is considered to play a role in the aetiology of midline diastema in the upper arch.<sup>17</sup> However, there is little evidence to support such a claim.<sup>18</sup> Clinically, patients are sometimes seen with a thick, fibrous fraenum, which is running between the incisors without the presence of a midline diastema (Figure 12) and, on other occasions, a diastema may be seen. At the present level of our knowledge, it is prudent to excise such a fraena surgically when it is considered to contribute to

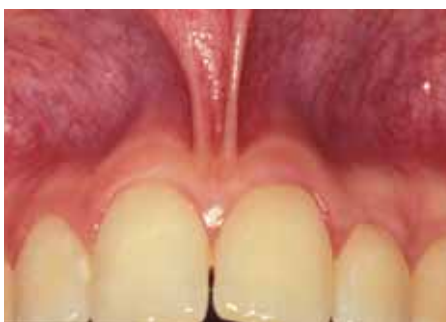relapse following treatment, or when it compromises gingival health by either pulling on the gingival margin or by interfering with efficient and effective toothbrushing.<sup>17,19</sup>

#### **Pathological condition**

Cystic lesions associated with the crown of a tooth can prevent its eruption. Dentigerous cysts occur commonly in the mandibular premolar and maxillary canine areas.<sup>20</sup> Removal of the entire cyst, along with the impacted tooth, is the main treatment to prevent the recurrence of the cyst. However, marsupialization of the cyst can save the cyst-associated tooth to allow its eruption.



**Figure 11.** Marked loss of attached gingiva labial to lower left canine.



**Figure 12.** Thick and fibrous upper labial fraenum.

All patients with such a condition should be treated in the hospital owing to the complicated nature of treatment involved.

### Stability/relapse

The orthodontically treated dentition is susceptible to relapse and most cases relapse to a small degree after retaining appliances are discarded. This is more likely to occur when the teeth are markedly rotated or spaced pre-treatment.<sup>21,22</sup> Another common finding is the late lower incisor crowding which occurs, even in untreated subjects. Following orthodontic alignment we cannot guarantee that the teeth will stay in their new position forever. A great deal of research has been carried out to investigate the exact causes of this orthodontic relapse and to find its remedy but, to date, all that can be said is that it is of multifactorial origin.<sup>23</sup> This should be explained to the patient at the outset. Removable retainers are often now provided and the patient has to wear them as long as they want a guarantee that the teeth will remain perfectly aligned.

### Conclusion

Orthodontic treatment is not without its limitations. These limitations could be related to the operator, patient and/or the appliance used, as were elaborated in the first part of this article. In addition, there are other limitations, which are related to the biology of the patient. The latter were described in this part of the article. It is important to be aware of these limiting factors when planning orthodontic treatment. These should all be explained to the patients before any treatment plan is adopted to ensure a fully informed consent is obtained.

### References

- Persson M, Thilander B. Palatal suture closure in man from 15 to 35 years of age. *Am J Orthod* 1977; **72**: 42–52.
- Melsen B. Palatal growth studies on human autopsy material. *Am J Orthod* 1975; **68**: 42–54.
- van Venrooy JR, Proffit WR. Orthodontic care for medically compromised patients: possibilities and limitations. *J Am Dent Assoc* 1985; **111**: 262–266.
- Burden D, Mullally B, Sandler J. Orthodontic treatment of patients with medical disorders. *Eur J Orthod* 2001; **23**: 363–372.
- Grundy MC, Shaw L, Hamilton DV. *An Illustrated Guide to Dental Care for the Medically Compromised Patient*. London: Wolfe Publishing, 1993.
- Boyd RL, Leggott PJ, Quinn RS, Eakle WS, Chambers D. Periodontal implications of orthodontic treatment in adults with reduced or normal periodontal tissues versus those of adolescents. *Am J Orthod Dentofac Orthop* 1989; **96**: 191–198.
- Melsen B, Agerbaek N, Eriksen J, Terp S. New attachment through periodontal treatment and orthodontic intrusion. *Am J Orthod Dentofac Orthop* 1988; **94**: 104–116.
- Hendelman CS. The anterior alveolus: its importance in limiting orthodontic treatment and its influence on the occurrence of iatrogenic sequelae. *Angle Orthod* 1996; **66**: 95–109.
- Hom BM, Turley PK. The effects of space closure of the mandibular first molar area in adults. *Am J Orthod* 1984; **85**: 457–469.
- Levander E, Malmgren O. Evaluation of the risk of root resorption during orthodontic treatment: a study of upper incisors. *Eur J Orthod* 1988; **10**: 30–38.
- DiBiase D. Midline supernumeraries and eruption of the maxillary central incisor. *Dent Pract Dent Rec* 1969; **20**: 35–40.
- Witsenburg B, Boering G. Eruption of impacted permanent upper incisors after removal of supernumerary teeth. *Int J Oral Surg* 1981; **10**: 423–431.
- Biederman W. The incidence and aetiology of tooth ankylosis. *Am J Orthod* 1956; **42**: 921–926.
- Bravo LA. Soft tissue profile changes after orthodontic treatment with four premolars extracted. *Angle Orthod* 1994; **64**: 31–42.
- Ackerman JL, Proffit WR. Soft tissue limitations in orthodontic: Treatment planning guidelines. *Angle Orthod* 1997; **67**: 327–336.
- DiBiase D. Mucous membrane and delayed eruption. *Trans Br Soc Study Orthod* 1969-70; **5**: 149–158.
- Edwards JG. The diastema, the fraenum, the frenectomy: a clinical study. *Am J Orthod*. 1977; **71**: 489–508.
- Sullivan TC, Turpin DL, Årtun J. A postretention study of patients presenting with maxillary median diastema. *Angle Orthod* 1996; **66**: 131–138.
- Shashua D, Årtun J. Relapse after orthodontic correction of maxillary median diastema: a follow-up evaluation of consecutive cases. *Angle Orthod* 1999; **69**: 257–263.
- Hyomoto M, Kawakami M, Inoue M, Kirita K. Clinical conditions for eruption of maxillary canines and mandibular premolars associated with dentigerous cysts. *Am J Orthod Dentofac Orthop* 2003; **124**: 515–520.
- Reitan K. Tissue rearrangement during retention of orthodontically rotated teeth. *Angle Orthod* 1958; **29**: 105–113.
- Little RM, Riedel RA. Post-retention evaluation of stability and relapse: mandibular arches with generalized spacing. *Am J Orthod Dentofac Orthop* 1989; **95**: 37–41.
- Richardson ME. Late lower arch crowding: the aetiology reviewed. *Dent Update* 2002; **29**: 234–238.